

## Article References

1. Chasen ST, Skupski DW, McCullough LB, Chervenak FA. Prenatal informed consent for sonogram: the time for first-trimester nuchal translucency has come. *J Ultrasound Med* 20:1147-1152, 2001.
2. Members of the FASTER Trial Consortium. First-trimester nuchal translucency screening. *J Ultrasound Med* 2002; 21: 481-2.
3. Chasen ST, Skupski DW, Chervenak FA, McCullough LB. First-trimester nuchal translucency screening: reply. *J Ultrasound Med* 2002; 21: 483-487.
4. Malone FD, Canick JA, Ball RH, Nyberg DA, et al. First-trimester or second-trimester screening, or both, for Down's syndrome. *N Engl J Med* 2005; 353: 2001-11.
5. Simpson JL. Choosing the best prenatal screening protocol. *N Engl J Med* 2005; 353: 2068-70.
6. Chervenak FA, McCullough LB. Implementation of first-trimester risk assessment for trisomy 21: ethical considerations. *Am J Obstet Gynecol* 2005; 192: 1777-81.
7. Nicolaides KH, Chervenak FA, McCullough LB, Avgidou K, Papageorghiou A. Evidence-based obstetric ethics and informed decision-making by pregnant women about invasive diagnosis after first-trimester assessment of risk for trisomy 21. *Am J Obstet Gynecol* 2005; 193: 322-6.
8. Falcon O, Auer M, Gerovassili A, Spencer K, Nicolaides KH. Screening for trisomy 21 by fetal tricuspid regurgitation, nuchal translucency and maternal serum free  $\beta$ -hCG and PAPP-A at 11 + 0 to 13 + 6 weeks. *Ultrasound Obstet Gynecol* 2006; 27: 000-000 Published online in Wiley InterScience (www.interscience.wiley.com). DOI: 10.1002/uog.2699
9. Huggon IC, DeFigueiredo DB, Allan LD. Tricuspid regurgitation in the diagnosis of chromosomal anomalies in the fetus at 11-14 weeks of gestation. *Heart* 2003; 89: 1071-1073.
10. Faiola A, Tsoi E, Huggon C, Allan LD, Nicolaides KH. Likelihood ratio for trisomy 21 in fetuses with tricuspid regurgitation at the 11 to 13 + 6-week scan *Ultrasound Obstet Gynecol* 2005;26(1):22-7. Published online in Wiley Inter Science (www.interscience.wiley.com). DOI: 10.1002/uog.1922.
11. Edwards A, Mulvey S, Wallace EM. The effect of image size on nuchal translucency measurement. *Prenat Diagn.* 2003 Apr;23(4):284-6.

## Upcoming Fetal Medicine Foundation United States Courses

\*Saturday February 18, 2006 in Newark NJ \* (6.75-8 CMEs possible)

\*Saturday March 4, 2006 in Chicago IL \* (6.75-8 CMEs possible)

\*Saturday April 1, 2006 in San Francisco CA \* (6.75-8 CMEs possible)

\*Saturday April 29, 2006 in San Juan, PR \* (6.75-8 CMEs possible)

Contact Melissa Machtolff 1-800-277-4363 (MMachtolff@genecare.com)

or Carrie Spradley 1-800-277-4363 (CSpradley @genecare.com) Website: www.genecare.com/35/id/Conferences

\*\*Thursday April 20, 2006 in Las Vegas, NV \*\* (7CMEs possible)

\*\*Saturday June 24, 2006 in New Haven CT \*\* (7CMEs possible)

\*\*Saturday September 9 in Columbus OH \*\* (7CMEs possible)

\*\*Saturday November 4 in Long Island NY \*\* (7CMEs possible)

\*\* Contact Ulla Buchner-Howard 1-212-288-9793 (ubuchner@ubhInternational.com)

or Colleen Bobb 1-212-230-1426 (colleen@ubhinternational.com) Website: www.ubhinternational.com/ultrasound.html

\*\*\*Online Fetal Medicine Foundation Course - [http://www.mfmedicine.com/phys\\_train2.aspx](http://www.mfmedicine.com/phys_train2.aspx) e-mail: John.Lai@mfmedicine.com\* \*\*



Naomi Greene MPH RDMS RDCS  
3940 Laurel Canyon Blvd. #838  
Studio City, CA 91604  
818-395-0611  
NaomiHG@fetalmedicine.com  
www.fetalmedicine.com/usa

### In this issue:

- **Ethics: An Essential Dimension of First Trimester Risk by Frank Chervenak, Laurence McCullough, Stephen Chasen (pg. 1)**
- **Tricuspid Regurgitation: Background and Accreditation Protocol (pg. 2)**
- **NT and Nasal Bone Scanning: Optimizing your ultrasound system (pgs. 2-3)**
- **FMF Software - News and Updates (pg. 3)**
- **Article References and Upcoming Courses (pg. 4)**

Please come and visit our  
Exhibit Booth at the  
**AIUM 2006  
Annual Convention**  
Washington DC  
March 24-26, 2006  
Booth #511

- **NT, Nasal Bone, and Tricuspid Accreditation, Software Information**
- **Free Textbook**
- **Reprints of recent publications**

FETAL MEDICINE FOUNDATION

January 2006

Volume 2 Issue 1

# 11-13<sup>+6</sup> Weeks Scan Project

## United States Newsletter

### Fetal Medicine Foundation United States Newsletter: New Developments and Articles from United States Experts

Welcome to the January 2006 issue of the FMF (USA) newsletter. In this issue you will find an article contributed by authors who are not only experts in prenatal screening and diagnosis but also have a special expertise in the field of medical ethics.

We are also including a brief description of the FMF protocol of

the evaluation of blood flow across the tricuspid valve in the first trimester and the steps needed to become accredited in this technique.

In addition, you will find an article containing tips for acquiring optimal NT measurements and nasal bone images,

which we hope you will find helpful. Finally, we are including information about upcoming Fetal Medicine Foundation courses.

I hope that you find this information useful and invite you to contact me with any questions (contact details in left margin of this page).

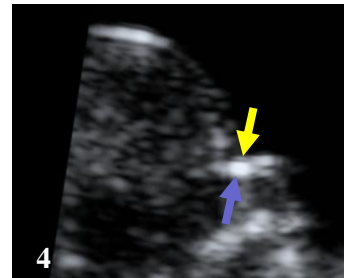
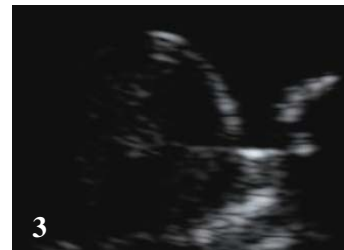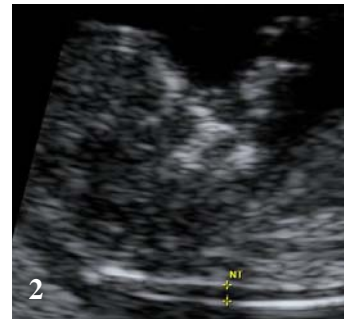
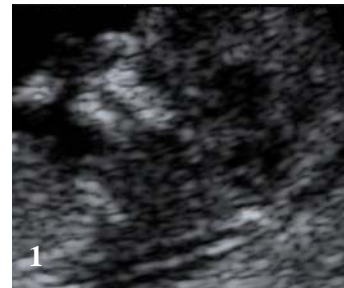
### Ethics: An Essential Dimension of First-Trimester Risk Assessment

Frank A. Chervenak MD\*, Laurence B. McCullough PhD\*\*, Stephen A. Chasen MD\*  
\*Department of Obstetrics/Gynecology, New York Weill Cornell Medical Center, New York, NY  
\*\*Center for Medical Ethics and Health Policy, Baylor College of Medicine, Houston, TX

In 2001 we argued that pregnant women should be offered first-trimester risk assessment for trisomy 21, provided, of course, that quality ultrasound is available.<sup>1</sup> We made this argument on the basis of respect for the autonomy of pregnant women and the already convincing evidence of reliability based on the experience of the Fetal Medicine Foundation. At the time, this was regarded as a controversial position.<sup>2,3</sup> The results of the FASTER trial, which was designed to study the comparative value of first-trimester vs. second-trimester

and first-trimester vs. integrated screening, have just been published: "Our results demonstrate that first-trimester screening for Down's syndrome is highly effective, but combinations of measurements of markers from both the first and second trimesters yield higher detection rates and lower false positive rates."<sup>4</sup> In an accompanying editorial Simpson comments: "First-trimester screening is thus clearly superior to screening in the second trimester."<sup>5</sup>

In effect, FASTER provides corroboration in a purely United States population for our autonomy-enhancement which was based on ethical analysis and argument and on the international population of the Fetal Medicine Foundation.<sup>6</sup> The merit of our strategy has recently been demonstrated in a study that showed that pregnant women use risk-assessment information to make decisions about subsequent invasive diagnosis that are sound and consistent with medical evidence.<sup>7</sup>



## Scanning tips for NT and nasal bone imaging: (continued)

... this can be accomplished by simply pressing a button, while in others, the user must choose to scan at a fundamental frequency when selecting a transducer and image preset. Image 1 (left side of this page), is taken with harmonics ON. Note the relatively fuzzy and thick lines outlining the NT area. Image 2 is taken in the same fetus with harmonics OFF. Notice that the lines are much sharper and clearer, facilitating a more accurate placement of the calipers. If you have questions about your particular ultrasound system, please feel free to e-mail me

(NaomiHG@fetalmedicine.com) and I will send you some specific suggestions for your system. No matter what the copyrighted names for special image-enhancing features are, my suggestion (insofar as NT scanning is concerned) would be to turn off all of the newer features and see whether this helps in making the lines that constitute the NT sharp and clear. Since we are concerned with image clarity, your main concern is to maximize the spatial resolution. The following will result in an improvement in contrast and sharper lines: adjust the dynamic range downwards, increase the edge enhancement, try cardiology settings which are designed for high-contrast imaging.

Nasal bone evaluation: I have found that harmonics can be helpful in bringing out the distinction between the nasal bone (thicker and brighter)

and the overlying skin (thinner and darker). Clear distinction between the two is a key component to establishing the presence of the nasal bone in the first trimester and obtaining accreditation in nasal bone assessment. In image 3 (left side of this page) harmonics is turned OFF and the nasal bone is difficult to distinguish from the overlying skin. Image 4 shows the nasal bone to be clearly present (blue arrow) and distinct from overlying skin (yellow arrow), and the only change in technique was to turn on harmonics.

Several of the manufacturers are showing an interest in producing "cheat sheets" or one-page handouts for their ultrasound systems to aid their clients in optimizing the settings for NT and nasal bone scanning. It may be a good idea to contact your Applications Specialist and ask them if such a document exists already for your system. If not, please feel free to give the Applications Specialist or Sales Representative my contact information (address, e-mail, and phone number on front page of newsletter, upper left-hand side) so that we can work together for success and accuracy.

In future issues of the newsletter, other issues regarding setting up ultrasound systems to help users obtain images that comply with the FMF criteria will be addressed. If there are particular aspects which you would like to see addressed, please don't hesitate to contact me or e-mail your suggestions.

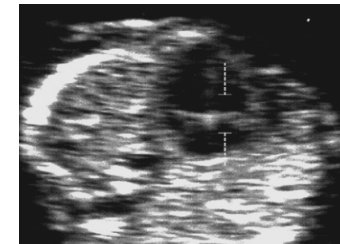## Fetal Medicine Foundation First Trimester Risk Calculation Software

The FMF offers its risk calculation program to anyone who earns the Certificate of Competence for Nuchal Translucency. The cost is a one-time fee of \$70 per CD and all FMF-accredited users in a practice can use the same software.

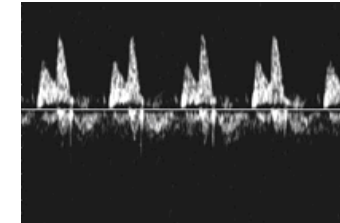
The program allows you to provide women with accurate patient- and fetus-specific risk of Down syndrome, and trisomies 18/13, even where there are more than two fetuses (the biochemistry can only be incorporated when there are one or two fetuses). The newest version of the software, just released, includes risk revision based not only NT and nasal bone, but also on assessment for tricuspid valve regurgitation (see article on page 2). Each of these elements can be used in the risk calculation once the accreditation process for that marker has been completed. For those who already have the previous version of the software, the newest version can be downloaded quickly and easily over the Net ([www.fetalmedicine.com/update](http://www.fetalmedicine.com/update)). For those who wish to obtain the

software, applications are taken over the Net as well—just go to <http://www.fetalmedicine.com/f-fmf.htm> and click on the link "Sybase license fee (software) online payment". You will be able to pay the fee with a credit card and will need to know your center's ID number and the FMF ID number for each person who will be using the software to calculate risk. I would be happy to give you this information, if needed.

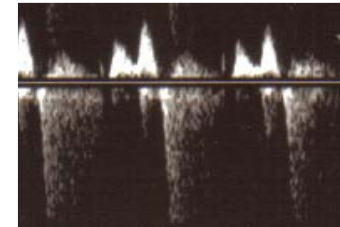
In addition to providing accurate risks for your patients, using the software makes the annual audit process very easy and provides an accurate picture of all the NTs done in your center. If a commercial lab submits your center's NT measurements for audit, the data may be incomplete. This is especially true if you use different labs over the course of a year. This may lead to confusion and a delay in the audit process.



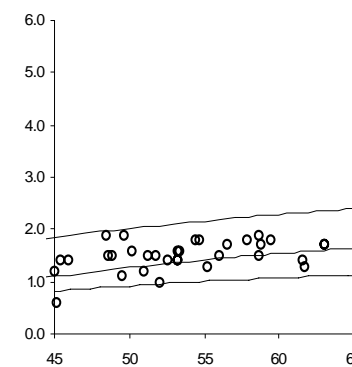
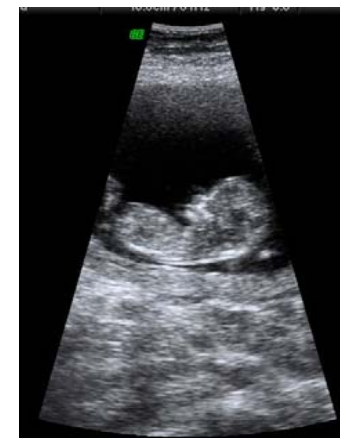4-chamber view 12 wks



Normal tricuspid flow



Abnormal tricuspid flow



## Tricuspid Regurgitation: Newest Ultrasound Marker to Be Included in First Trimester Risk Calculation

Recent publications have demonstrated the relationship between tricuspid regurgitation in the first trimester and trisomy 21<sup>8,9</sup> and evaluated its association with NT, free beta hCG and PAPP-A<sup>10</sup>. Inclusion of tricuspid regurgitation along with NT and biochemistry can yield detection rates of 95%, 90%, 87% for false-positive rates of 5%, 2%, and 1%, respectively, when performed by ultrasound providers who received adequate training and demonstrated competence by FMF protocols<sup>10</sup>.

In late 2005, the Fetal Medicine Foundation introduced its updated risk calculation algorithm which includes NT / nasal bone / tricuspid regurgitation along with free beta hCG and PAPP-A. Those who have previously received the FMF Certificate of Competence for NT measurements may obtain further accreditation(s) in nasal bone and/or tricuspid regurgitation. The protocol for accreditation in nasal bone assessment has been previously outlined in the last newsletter and this

information is also available at [www.fetalmedicine.com/usa](http://www.fetalmedicine.com/usa).

The requirements for obtaining accreditation for first trimester evaluation of tricuspid regurgitation is:

1. FMF certification in the 11-13+6 weeks scan (i.e. nuchal translucency)
2. Participation in the FMF audit of the distribution of NT measurements and images and demonstration of satisfactory performance
3. Attendance of a recent FMF 11-13+6 Weeks Scan course, including a lecture on the assessment of the fetal tricuspid flow or receipt and review of the printed protocol (please e-mail me to receive this and/or with any questions @ NaomiHG@fetalmedicine.com)
4. Submission of a logbook of 5 images demonstrating tricuspid flow, including at least one with tricuspid regurgitation

## Scanning tips for NT and nasal bone imaging: getting the most of your ultrasound system

The biggest challenges to obtaining NT images that comply with the Fetal Medicine Foundation criteria appear to be two-fold:

- 1) Adequately magnifying the fetal head and thorax, and
- 2) Producing images in which the lines that make up the NT are crisp and clear.

Issue (1): This seems to arise especially with older ultrasound systems as many of the newer systems have the ability to use pre- and post-processing methods of magnification. The goal is to fill the image area with the fetal head, neck, and upper thorax. Reducing the depth (so that the fetus is almost at the bottom of the sector) and narrowing the sector width (to include only the upper part of the fetus) before magnifying will increase the resolution of the NT area in the magnified image. With adequate magnification, each movement of the calipers should change the measurement by the recommended 0.1mm. With a suboptimal magnification, this level of precision is not achieved, usually leading to an overestimation of the NT. The association between in-

adequate magnification and larger-than-expected NT measurements has been confirmed in a recently published report<sup>11</sup>. The distribution of NT measurements in the bottom figure on the left is skewed toward higher than expected (71.7% above the median whereas it would be expected that 40-60% should be above the median) while, as seen from the NT image above it which is typical of the images that produced this distribution, the major error in technique is that the fetus is insufficiently magnified.

When magnifying, the following steps may be helpful in trying to maximize the resolution of the enlarged fetus: before magnifying, narrow the sector width and reduce the overall depth—this will increase the scan lines in the magnified area.

Issue (2): This problem seems to pertain to newer ultrasound systems that offer image enhancing modalities such as tissue harmonics. While some of the very newest types of harmonic imaging may help increase the resolution of the NT region, in general, it is recommended that harmonics be turned OFF for the NT measurement.