



## Fetal Medicine Foundation First Trimester Examination of the Fetal Nasal Bone

### First Trimester Examination of the Fetal Nasal Bone

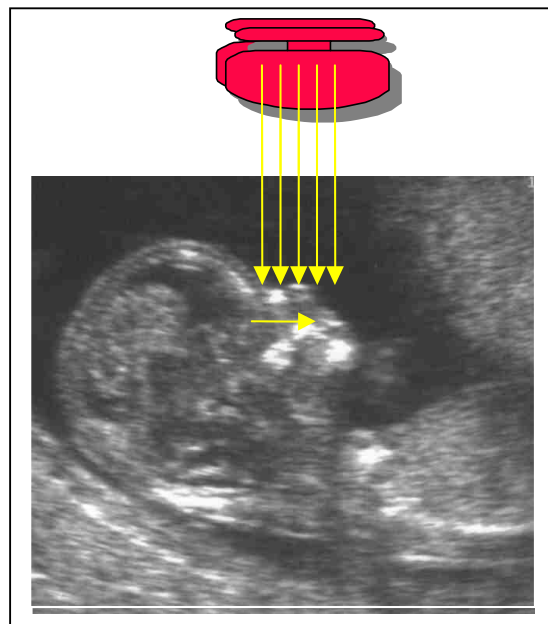
The findings of recent studies suggest that examination of the fetal profile at 11-13<sup>+6</sup> weeks could have major beneficial implications in screening for Trisomy 21 by maternal age and fetal nuchal translucency (NT). However it is imperative that, as for the NT scan, sonographers undertaking risk assessment by examination of the fetal profile must receive appropriate training and certification of their competence in performing the nasal bone scan.

This document describes the Fetal Medicine Foundation:

1. Protocol for the assessment of fetal nasal bone
2. Clinical application of nasal bone findings
3. Certification in the first trimester assessment of the fetal nasal bone

### Protocol for the assessment of fetal nasal bone

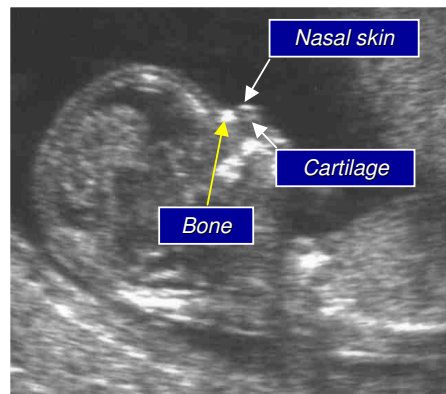
1. The gestational period must be 11 to 13<sup>+6</sup> weeks - the nasal bones first appear at a crown-rump length of 42 mm and increase linearly with gestation.
2. The magnification of the fetus must be such that only the head and upper thorax are present on the screen
3. A mid sagittal section of the fetal profile must be obtained with the ultrasound transducer held parallel to the direction of the nose. The ultrasound transducer should be gently tilted from side to side to ensure that the nasal bone is seen separate from the nasal skin.



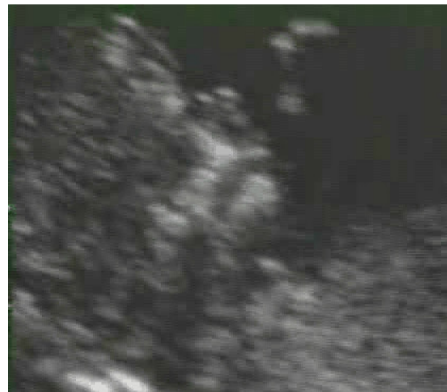

## Fetal Medicine Foundation First Trimester Examination of the Fetal Nasal Bone

4. The echogenicity of the nasal bone should be greater than the skin overlying it. In this respect, the correct view of the nasal bone should demonstrate three distinct lines:
  - The first two lines, which are proximal to the forehead, are horizontal and parallel to each other, resembling an “equal sign”. The top line represents the skin and bottom one, which is thicker and more echogenic than the overlying skin, represents the nasal bone.
  - A third line, almost in continuity with the skin, but at a higher level, represents the tip of the nose.



Absence of the bottom line of the equals sign represents the absence of the fetal nasal bone



When the nasal bone line appears as a thin line, less echogenic than the overlying skin, it suggests that the nasal bone is not yet ossified, and it is therefore classified as being absent



## Fetal Medicine Foundation First Trimester Examination of the Fetal Nasal Bone

### Clinical application of nasal bone findings

The incidence of an absent nasal bone is related to NT, CRL and ethnic origin as well as aneuploidy, being more common with increased NT, smaller CRL measurements and fetuses of Afro-Caribbean parents. Therefore it is not possible to give simple numbers by which the presence of the nasal bone will reduce the risk for Trisomy 21 and the absence will increase the risk. It is essential that those adjusting the risk for Trisomy 21 using the finding of the presence or absence of the fetal nasal bone do so with recognized risk calculation software that takes into account all the appropriate parameters. The Fetal Medicine Foundation ~~will release such~~ risk calculation software ~~in October, but will only make it available to sonographers who have been appropriately trained and accredited in the assessment of the fetal nasal bone.~~

The presence of the fetal nasal bone is reassuring and will be particularly useful for patients with risks between 1 in 150 and 1 in 300 who are traditionally classified as screen positive, but with the presence of the nasal bone confirmed, may be sufficiently reassured.

The difficulty is in a patient with a low risk result from NT (with or without serum biochemistry) when the nasal bone appears to be absent. An absent nasal bone will increase dramatically the risk for Trisomy 21, but our advice is that such patients are rescanned in one week and action is only taken at that point if there is persistence of the absence of the nasal bone.

### Certification in the first trimester assessment of the fetal nasal bone

The requirements for certification in first trimester assessment of the fetal nasal bone are:

- FMF certification in the 11-13<sup>+6</sup> weeks scan
- Participation in the FMF audit of the distribution of NT measurements and images and demonstration of satisfactory performance
- Attendance of a recent FMF 11-13<sup>+6</sup> Week Scan course, including a lecture on the assessment of the fetal nasal bone
- Submission of a logbook of 5 images demonstrating the presence of the fetal nasal bone – please do **not** include measurements of the nasal bone. Only assess its presence or absence.
- There is no fee for this accreditation process.

Please send your completed logbook images to:

Naomi Greene MPH RDMS RDCS  
Fetal Medicine Foundation  
3940 Laurel Canyon Blvd. #838  
Studio City, CA 91604

e-mail: NaomiHG@fetalmedicine.com